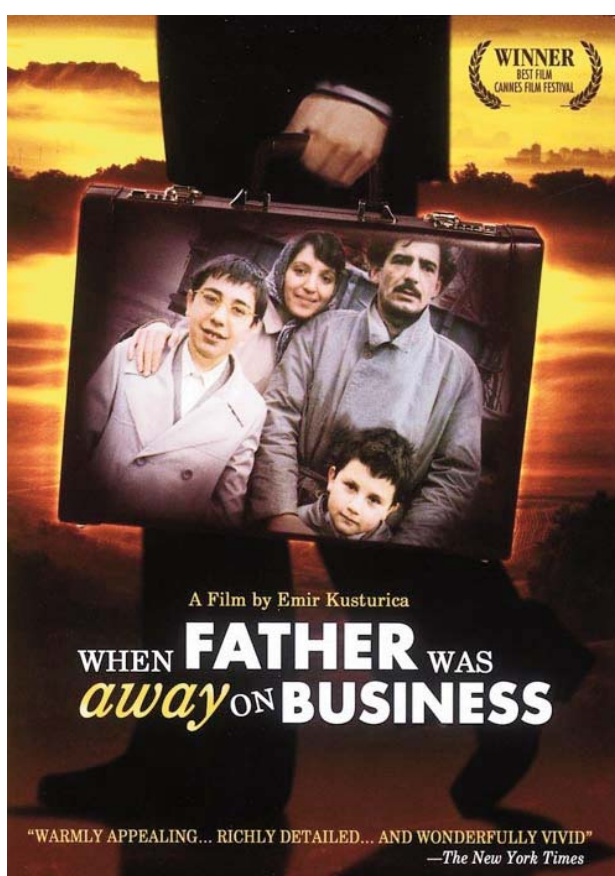


## Domestic Circumcision by Guided Forceps Technique



Action: Yugoslavia, in the fifties of the last century.  
Poster in English

### Technical Details

**Original Title:** *Otac na službenom putu.*

**Other Titles:** *When Father Was Away on Business* (English), *Papá salió en viaje de negocios* (Argentina), *Cuando Papá se va de viaje* (Méjico), *Papá está en viaje de negocios* (Spain).

**Country:** Yugoslavia.

**Year:** 1985.

**Director:** Emir Kusturica.

**Music:** Zoran Simjanović.

**Photography:** Vilko Filac.

**Film Editor:** Andrija Zafranović.

**Screenwriter:** Abdulah Sidran.

**Cast:** Moreno de Bartolli, Miki Manojlović, Mirjana Karanović, Mustafa Nadarevic, Mira Furlan, Pedrag Lakovic, Pavle Vujisic, Slobodan Aligrudic, Eva Ras, Aco Djorcev, Emir Hadzihafizbegovic, Zoran Radmilovic, Zoran Radmilovic,...

**Color:** Color.

**Runtime:** 136 minutes.

**Genre:** Drama.

**Language:** Serbian and hungarian.

**Production Company:** Centar Film and Forum Sarajevo.

**Synopsis:** Tito's break-up with Stalin in 1948 marked the beginning of not only confusing, but also very dangerous years for many hard-core Yugoslav communists. A careless remark about the newspaper cartoon is enough for Mesha to join many arrested unfortunates. His family is now forced to cope with the situation and wait for his release from prison. The story is told from the perspective of Malik, his young son who believes the mother's story about father being "away on business".

**Awards:** Nominated for an Academy Award (Oscar) in the category of Best Foreign Language Film. (1986). Won FIPRESCI Prize and Palme d'Or at Cannes Film Festival (1985).

**Free full movie:**

<http://video.google.com/videoplay?docid=-7161376293373794285#>  
(2012/01/04)

**Links:**

<http://www.imdb.com/title/tt0089748/>

<http://www.filmaffinity.com/es/film843652.html>



Hand-washing before the procedure.



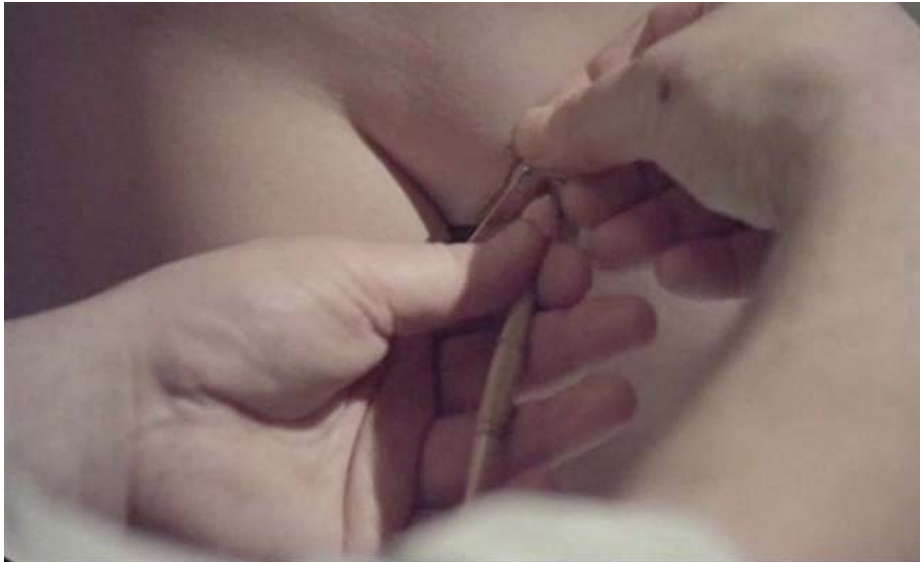The boy is held tightly to prevent any sudden movements.



Foreskin is fixated and pulled forward over the head of the penis.



Circumcision set on the floor.



Placement of a forceps so that skin along its outside edge can be cut.



Forceps in place enabling guidance of the incision and protection of the penis from injury.



Preparation for cutting foreskin with a razor.



Painful grimace on boy's face considering no local anesthesia was used.

**Tomislav Meštrović**

Polyclinic for Medical Microbiology and Parasitology, Gynecology, Internal Medicine, Urology and Occupational Medicine "Dr. Zora Profozić", Bosutska 19, 10000 Zagreb (Croatia).

Correspondence: Tomislav Meštrović, Andrije Hebranga 23, 10430 Samobor (Croatia).

e-mail: [tomislav.mestrovic@gmail.com](mailto:tomislav.mestrovic@gmail.com)