

RADIOLOGICAL EVALUATION OF A FOSSIL TURTLE TRAUMA FROM THE UPPER JURASSIC OF EICHSTÄTT (TESTUDINES: CRYPTODIRA)

[Evaluación radiológica de un traumatismo en una tortuga fósil del Jurásico Superior de Eichstätt (Testudines: Cryptodira)]

Mark R. MCCOY¹

Hans-Volker KARL^{2,3}

Gottfried TICHY⁴

Jürgen STEINBACHER¹

Georg AIGNER¹

Jan CEMPER-KISSLICH⁵

¹ Paracelsus Medical University-Salzburg-Division of Neuroradiology. Christian Doppler Clinic. Ignaz-Harrerstraße 79. A-5020 Salzburg, Austria. Correo-e: m.a.mccoy@salk.at

² Thüringisches Landesamt für Denkmalpflege und Archäologie. Humboldtstraße 11. D-99423 Weimar, Germany. Correo-e: hvkarl@web.de

³ Geoscience Center of the University of Göttingen. Department of Geobiology. Goldschmidtstrasse 3. D-37077 Göttingen, Germany

⁴ University of Salzburg. Department of Geography and Geology. Hellbrunner Strasse 34. A-5020 Salzburg. Correo-e: gottfried.tichy@sbg.ac.at

⁵ University of Salzburg. Interfaculty Department of Legal Medicine. Ignaz-Harrerstraße 79. A-5020 Salzburg, Austria. Correo-e: Jan.Kiesslich@sbg.ac.at

(FECHA DE RECEPCIÓN: 2011-12-12) (FECHA DE ADMISIÓN: 2012-01-05)

BIBLID [0211-8327 (2012) 48 (1); 37-44]

RESUMEN: Los estudios radiológicos en los objetos fósiles son una parte necesaria de la evaluación científica desde hace muchos años. Se presenta el caso de una tortuga fósil del Jurásico Superior (Testudines: Cryptodira) de Eichstätt en Alemania, que muestra un estado traumático. Con rayos X y TAC pueden verse los cambios postraumáticos. Se trata de cavidades llenas de aire que se deben probablemente a un barotrauma masivo. Estos exámenes se han realizado en hospitales debido a la carencia de equipos especiales de rayos X.

Palabras clave: Jurásico Superior, tortuga con marcas de mordiscos, evaluación de rayos X y TAC, ataque crocodiliano.

ABSTRACT: Radiological studies on paleontological objects are a necessary part of the scientific evaluation since many years. We present a case of a fossil turtle from Upper Jurassic (Testudines: Cryptodira) of Eichstätt in Germany, which shows a traumatic event. By X-ray and CT of the specimen posttraumatic changes can be seen. These are air filled cavities which are probably due to a massive barotrauma. Because of the lack of special X-ray equipment usually such examinations are done in hospitals.

Key words: Upper Jurassic turtle with, bite marks, X-ray and CT evaluation, crocodile bite attack.

INTRODUCTION

Paleoradiology is the study of bioarcheological material using modern methods, such as radiography (MRI), computed tomography (CT), magnetic resonance imaging and micro - CT.

(CHHEM & BROTHWELL, 2008). The investigation of palaeopathological finds has a long tradition as investigation of ROBINSON & KESSLER (1987), HARBERSETZER (1994), and LONGBOTTOM (2005) have shown. Even new turtles could be described by the use of CT (LIPKA *et al.*, 2006). In the absence of diagnostic equipment specifically for the paleoradiology, again and again X-ray and CT devices for human medicine are used. But, with these devices, an X-ray examination is only possible when the find is not too thick and the application of computed tomography for our purposes is limited because these CT are only calibrated devices on the medical application. Special devices for the investigation of fossils would be of advantage. For us, the questions were among others if such cavities, we observed, are already known in paleontology. Can these cavities without sediment fillings be explained by the explosive barotrauma or perhaps with a rupture of the lung, or with the traumatic opening of the vertebral canal. Or is it the result of the formation of a gas in the context of autolysis?

MATERIALS AND METHODS

FOSSIL SPECIMEN: Complete specimen of *Eurysternum wagneri*, female, Eichstätt, IGPS 649, coll. Stefan Schäfer (Puchheim), KARL & TICHY (2004, 2006, 2011).

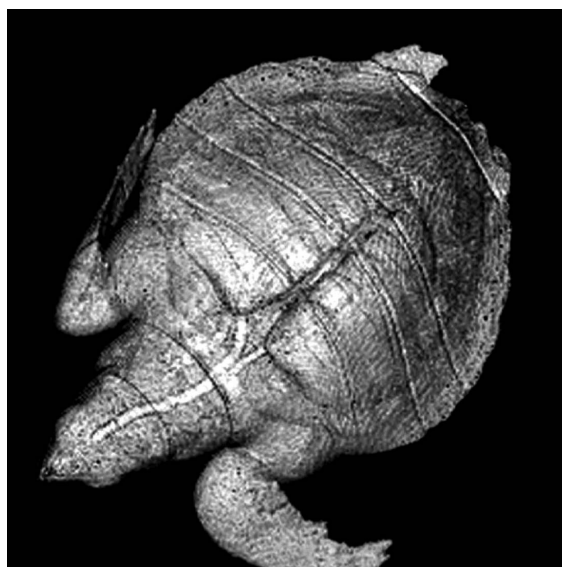
X-RAY: Philips Horizontal Diagnost H.

COMPUTER TOMOGRAPHY: Philips brilliance 10 - spiral CT.

The investigation was carried out by 120 kV and tube voltage and a current time product of 400 m as, thickness 1 mm.

RESULTS

The X-ray shows a multiple broken/rough carapace of a turtle carapax with excellent quality of the images of the partially exposed fossil. Here you can see a series of rounded destructions that could fit roughly to a mouth of a crocodile-like animal (KARL & TICHY, 2004, 2006; KARL, 2012). The cervical spine is torn up. Conspicuous air pockets - without sediment fillings can be observed in the area of the cranium, the spinal canal, the spinal nerve ends, below the broken carapace, and other cavities close to the extremities. Despite the low penetration depth the computed tomography shows the air-filled cavities particularly well under the surface-exposed sections of the skull and spine. Complementary studies conducted by other fossil turtles showed no air inclusions, as in the other two specimens presented by KARL & TICHY (2006) (IGPS 650 and IGPS 651). Figure 1 showing a CT scan of position the lungs in a specimen of *Lepidochelys kempii* using a figure of WYNEKEN (2001). It is noteworthy that the dorsal surfaces of the lungs directly be on the median visceral surface of the carapace. Here, the cause of the gas discharge can be supposed according our CT-scans at plate 1 in compare with the fossil bite marks in figure 2.



*Figure 1. CT scan showing the lungs in a specimen of *Lepidochelys kempii* using a figure of WYNEKEN (2001). Remarks that the medial surfaces of lungs are attached to the vertebral column. With permission from Jeannette Wyneken.*

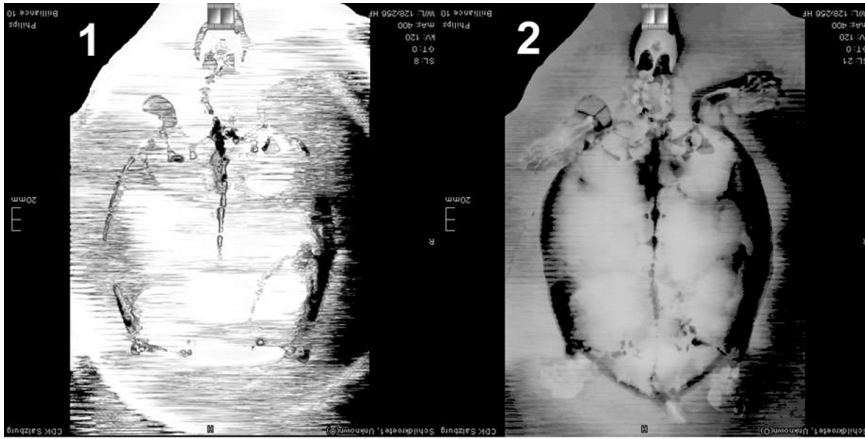


Plate 1a. 3D Volume rendering - showing air filled spaces; figure 1: X-ray showing the traumatic disruption of the spinal column and air-filled spaces in the vertebral canal; figure 2: 3D volume rendering - showing air-filled spaces.

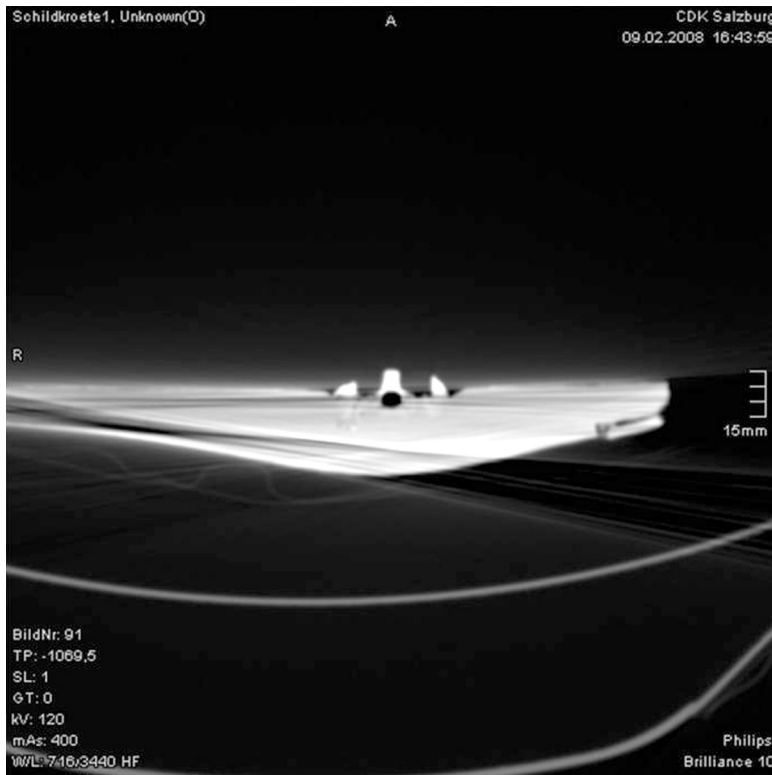


Plate 1b. CT depicting the air-filled vertebral canal in vertical section.

RECONSTRUCTION OF A POSSIBLE SCENARIO

A crocodile captured the turtle with the right tooth bar in the anterior third of the carapace, with the teeth came through the thin bones and which have been partly wedged. Here the main branches of the peripheral back nerves just below the perforation were hit and their dura were torn. This, some parts of the tube could be ventilated and therefore could not be filled with sediment during the autolysis. This is the reason why the cavities in the internal cast still are preserved. These can be shown by the the light tube-shaped structure in the x-ray pictures.

After the first bite in the anterior third of the carapace, the crocodile tried to get a better position of the asymmetric taken prey into its mouth. This occurs in crocodiles by short jerky movements of throwing and with a immediate repeated snapping. In this case, are the bite marks of the left tooth bar at the posterior third of the carapace the reason for this assumption. The turtle defended itself against this attack by heavy legs stomping and dorsal stretched out neck as well as by abrupt hitting with the head.

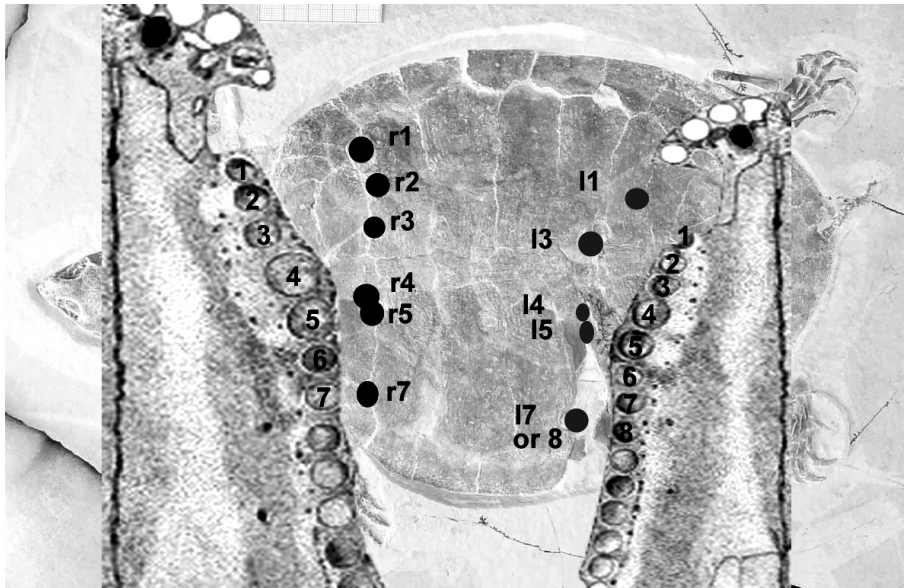


Figure 2. *Eurysternum wagleri*, female, Eichstätt, IGPS 649, Übersichtsaufnahme mit den Bißmarken und Markierung der einzelnen Zabneindrücke: r1-r6 = first maxillary teeth of the right side, l1-l6 = first maxillary teeth of the left side (l2 is absent). For comparison, the corresponding afford his dental of *Goniopholis simus* Owen, 1878, the "Obernkirchen Sandstone" hollow mould, private collection of Willi Adam, drawn after the silicon mould by Elke Gröning, Clausthal. Adapted from KARL et al. (2006).

On this occasion a left canine of the crocodile certainly stuck deeply in the dorsal side of the neck, which led to a large tear-down of the dorsal processus of the cervical vertebrae during throw over to the right side of the crocodile's mouth. This event certainly led to immediate death of the turtle especially since the neck market was badly damaged, if not severed.

Whether in this case a single individual using change of chewy bars or two roughly equal predators fighting over the loot cannot be determined with certainty. The latter could be supposed by some differences in the dental items with each other, especially from r4 14, l5 r5 and r6 l6 to each other (figure 2).

DETERMINATION OF THE FOSSIL PREDATOR

None of the crocodiles, from the south German Lithographic stone (Lithographen Schiefer) which are listed by FRICKHINGER (1994) can be considered as to be the producer of bite tracks. On the one hand, they are too small and fragile to produce such bites such as *Aelodon* (synonym of *Steneosaurus*), *Alligatorellus*, *Alligatorium* and *Atoposaurus*. On the other hand, the big ones, such as *Dacosaurus*, *Geosaurus* and *Steneosaurus* have no constriction between the praemaxillaria and maxillaria and. These long-snouted crocodiles are represented by the family Metriorhynchidae Fitzinger, 1843, as well as by the subfamilies Geosaurinae Lydekker, 1889 (*Dakosaurus* of Quenstedt, 1856; *Geosaurus* Cuvier, 1824). See also Fraas (1901, 1902) and Teleosauridae Geoffroy Saint Hilaire, 1831 (*Steneosaurus* Geoffroy, 1825). The double canins of maxillar teeth 4/5 are typical features for the Upper Jurassic and Lower Cretaceous species of *Goniopholis*. *Goniopholis* Owen, 1841 is the type genus of the Goniopholididae Cope, 1875. Relevant material from North-East Germany was described by KARL *et al.* (2006 and 2008). Table 3, figure 2 shows the striking similarity of the dental impressions with its comparable tooth position with *Goniopholis*.

Figure 3 shows a wild crocodile launches attack on sea turtle on the beach at Duyfken Pt on Cape York Peninsula. That saltwater crocodile *Crocodylus porosus* (Schneider, 1801) get also the double canines of maxillar teeth 4/5. It is the recent model for the Upper Jurassic/Lower Cretaceous *Goniopholis*.

DISCUSSION

Such a case is not known from literature. But, such good preservation is very rare. Also, traces of a clash of two animals are quite exceptional. The now proven cavities most likely are related to the trauma, especially since they are directly connected with the lesions in the skeleton. From radiological point of view the traumatic origin seems most likely. A formation of cavities due rotting gas is unlikely, because the gas would have cut themselves a way through softer and autolysed material, including the destruction of thin areas of the carapace, which often can be observed during the preparation.



Figure 3. Wild crocodile launches attack on turtle on the beach at Duyfken Pt on Cape York Peninsula. Pic: Aaron and Naomi Vickers Source: The Courier-Mail. It is a saltwater crocodile *Crocodylus porosus* (Schneider, 1801).

ACKNOWLEDGEMENT

We greatly thank Stefan Schäfer (Fürstfeldbruck) who provided us with the fossil and for the permission to publish his important material.

BIBLIOGRAPHY

- CHHEM, R. K. & BROTHWELL, D. K. (Eds.) (2008): *Imaging Mummies and Fossils in Paleoradiology*. Springer, Berlin, Heidelberg, New York, p. 1.
- BROIN, F. de (1994): Données préliminaires sur les chéloniens du Tithonien inférieur des calcaires lithographiques de Canjuers (Var, France). *Geobios*, **16**: 167-175.
- DE LAPPARENT DE BROIN, F.; LANGE-BADRÉ, B. & DUTRIEUX, M. (1996): Nouvelles découvertes de tortues dans le Jurassique Supérieur du Lot (France) et examen du taxon Plesiochelyidae. *Revue de Paléobiologie*, **15**: 533-570.
- FRAAS, E. (1901): Die Meerkrokodile (*Thalattosuchia* n. g.) eine neue Sauriergruppe der Juraformation. *Jahreshefte des Vereins für vaterländische Naturkunde Württembergs*, **57**: 409-418.

- FRAAS, E. (1902): Die Meer-Krokodilier (Thalattosuchia) des oberen Jura unter spezieller Berücksichtigung von *Dacosaurus* und *Geosaurus*. *Paleontographica*, **49**: 1-72.
- FRICKHINGER, K. A. (1994): *Die Fossilien von Solnhofen*. Goldschneck-Verlag, Korb, 336 pp.
- HARBERSETZER, J. (1994): Radiography of Fossils. In: LEIGGI, P. & MAY, P. J. (Eds.): *Vertebrate Paleontological Techniques*. Vol. 1. Cambridge University Press, Cambridge, pp. 329-339.
- KARL, H.-V. (2012): Bite traces in a turtle shell fragment from the Kimmeridgian (Upper Jurassic) of northern Germany. *Studia Palaeoichthyologica*, **4**: 25-30.
- KARL, H.-V.; GRÖNING, E.; BRAUCKMANN, C. & KNÖTSCHKE, N. (2008): First remains of the head of *Steneosaurus* (Crocodylomorpha: Teleosauridae) from the Late Jurassic of Oker (Lower Saxony, Germany). *Stud. Geol. Salmanticensia*, **44** (2): 187-201.
- KARL, H.-V.; GRÖNING, E.; BRAUCKMANN, C.; SCHWARZ, D. & KNÖTSCHKE, N. (2006): The Late Jurassic crocodiles of the Langenberg near Oker, Lower Saxony (Germany), and description of related materials (with remarks on the history of quarrying the "Langenberg Limestone" and "Obernkirchen Sandstone"). *Clausthaler Geowissenschaften*, **5**: 59-77.
- KARL, H.-V. & TICHY, G. (2004): The structure of fossil teeth of chelonophagous crocodiles (Diapsida: Crocodylia). *Stud. Geol. Salmanticensia*, **40**: 115-124.
- KARL, H.-V. & TICHY, G. (2006): Treffpunkt Forschung/Paläontologie/Altmühltal: neue Schildkrötenfunde im Plattenkalk. *Biologie in unserer Zeit*, **4/2006**: 18-19.
- LIPKA, T. R.; THERRIEN, F.; WEISHAMPEL, D. B.; JAMNICZKY, H. A.; JOYCE, W. G.; COLBERT, M. W. & BRINKMAN, D. B. (2006): A new turtle from the Arundel Clay facies (Potomac Formation, Early Cretaceous) of Maryland, U.S.A. *Journal of Vertebrate Paleontology*, **26** (2): 300-307.
- LONGBOTTOM, A. (2005): The use of X-rays in paleontology. Set in stone NHM. (*Paleo*) *Newsletter*, **3**: 8-10.
- ROBINSON, R. & KAESLER, R. L. (1987): Phylum Arthropoda. In: BOARDMAN, R. S.; CHEETHAM, A. H. & ROWELL, A. J. (Eds.): *Fossil intervertebrates*. Blackwell, London, pp. 205-269.
- WENHAM, M. (2010): Australia's saltwater crocodiles ride tidal and ocean currents to cover long distances. *The Courier-Mail*, June 08, 2010, 1: 08AM (Aaron and Naomi Vickers Source). <<http://www.dailytelegraph.com.au>>.
- WYNEKEN, J. (2001): *The Anatomy of Sea turtles*. U.S. Department of Commerce NOAA Technical Memorandum NMFS-SEFSC-470: 1-172.