

Cold Sore, Cold Soul?

An Examination of Orolabial Herpes in Film

Alex C. Holliday¹, Amanda Salih¹, Richard F. Wagner, Jr. ^{1,2}

¹The University of Texas Medical Branch Galveston, Texas 77555-0783 (USA).

²Edgar B. Smith Professor of Dermatology.

Correspondence: Richard F. Wagner. The University of Texas Medical Branch Galveston, Texas 77555 (USA).

e-mail: rfwagner@utmb.edu

Received 9 September 2013; accepted 24 September 2013.

Summary

The sociocultural phenomenon of herpes is attributed to two strains of the herpes simplex virus: herpes simplex virus type 1 (HSV-1) causes orolabial cold sores while herpes simplex virus type 2 (HSV-2) is typically identified in genital lesions, though both viruses may cause clinically similar signs and symptoms anywhere in or on the body. While these infections are extremely prevalent and typically benign, media sources such as film have perpetuated a negative public perception of the disease. Thus, a large portion of society continues to associate these conditions with sexual misconduct and moral failing. Despite decades of available antiviral therapy to shorten and suppress outbreaks, movies continue to exploit herpes for degradation and for humor. Portrayal of genital herpes in films is avoided in order to avert unnecessary and grotesque nude scenes, so depictions of cold sores are preferred. This article analyzes the use of orolabial herpes lesions in selected English language films released from 1984-2012.

Keywords: Herpes, Cold sore, Fever blister, Skin, Cinema, Stigmatization.

Resumen

El fenómeno sociocultural del herpes se debe a los dos tipos del virus de herpes simple: el virus del herpes simple tipo 1 (HSV-1) que causa el herpes labial, y el tipo 2 (HSV-2) que se identifica normalmente en lesiones genitales, aunque ambos virus pueden causar signos y síntomas similares en cualquier lugar del cuerpo. A pesar de que estas infecciones son de elevadísima prevalencia y típicamente benignas, los medios de comunicación y el cine han dado una percepción negativa de las mismas. Así, una gran parte de la sociedad continua asociando estos problemas a conductas sexuales irresponsables y valores morales deteriorados. Aunque desde hace décadas existe terapia antiviral para acortar y suprimir los brotes, el cine continúa explotando esta enfermedad para crear situaciones humillantes o cómicas. La representación del herpes genital en las películas suele evitarse a fin de huir de escenas de desnudos innecesarias y grotescas, apareciendo las aftas bucales de forma mucho más común. El artículo analiza el uso de las lesiones orales herpéticas en películas de habla inglesa desde el año 1984 hasta 2012.

Palabras clave: herpes, herpes labial, herpes febril, piel, cine, estigmatización.

The author's state that this article is original and has not been previously published.

Introduction

In modern times the public is inundated with various media channels such as the Internet, books, television, and movies. An unfortunate consequence of this bombardment is the possibility of disseminating misinformation. This is of particular concern when health care is involved because people partially rely on media outlets to acquire medical information¹. A film's portrayal of a disease, whether frank or subtle, has the potential to influence society's perceptions, attitudes, and behaviors toward that particular disease. Movies often use the public's view of a disease to facilitate characterization. This research explores how filmmakers exploit the negative connotations associated with orolabial herpes principally to stigmatize characters and to inject humor. Our focus is on selected English language films from 1984-2012 (Table 1), with emphasis on a recent movie, *The Help* (2011).

The sociocultural implications of herpes perpetuated by film may contribute to and skew society's understanding of medical facts and lead to negative consequences for those with the viral infection. Film characterizations of herpes may also hamper efforts by health-care providers to educate people about transmission, prevention, and early intervention. An article from *Health Affairs* acknowledged that accurate health communications through entertainment media are desirable¹. Thus, it is imperative that healthcare professionals remain mindful and critically examine the ways in which diseases are portrayed in media such as film.

Additionally, others have recognized the treatment of herpes in media has distorted and shaped the general interpretation of the disease².

Colloquially known as a "cold sore" or "fever blister" and clinically as "gingivostomatitis" or "herpes labialis," orolabial herpes is common. The herpes simplex virus type 1 (HSV-1) is responsible for the majority of perioral and oral mucosal lesions while herpes simplex virus type 2 (HSV-2) contributes to most genital infections and affects approximately 1 in 5 Americans, particularly lower socioeconomic groups³. However, it is possible for either type of HSV to cause lesions anywhere on the body⁴. Overall, seroprevalence of the two viruses varies greatly by geography, population subgroup, sex, and age. HSV-1 is typically more common than HSV-2 and increases in an almost linear fashion with age. HSV-1 prevalence reaches about 40% by 15 years of age, and then rises to 60%–90% in the elderly⁵. Serious manifestations such as ocular infections⁶, meningoencephalitis⁷ and neonatal disease⁸ are possible with either virus. Recently, herpes has been implicated in Alzheimer's disease⁹.

During the initial infection the virus produces multiple vesicles and papules that coalesce into larger pustular or ulcerative areas, eventually forming crusts before resolution. Fever, malaise, dysuria, local pain and pruritus, and tender regional adenopathy are often appreciated¹⁰. Following resolution, herpes remains dormant in the sensory neuronal ganglia, specifically the lumbosacral or trigeminal ganglion, poised for reactivation⁸. Reactivation

Table 1. Chronology of Films Featuring Cold Sores.

<i>This is Spinal Tap</i> (1984).	Comedy, Musical.	Nigel and David, Band members.
<i>The Princess Bride</i> (1987).	Adventure, Comedy, Family.	"The Albino," Keeper of the Pit of Despair and executioner.
<i>The Lord of the Rings: The Two Towers</i> (2002).	Action, Adventure, Fantasy.	Grima Wormtongue, Ally of villain Saruman.
<i>Smokin' Aces</i> (2006).	Action, Thriller, Comedy.	Rupert "Rip" Reed, Lawyer.
<i>Pineapple Express</i> (2008).	Action, Comedy, Crime.	Red, Drug dealer.
<i>The Help</i> (2011).	Drama.	Hilly Holbrook, Southern Queen Bee/Villain.
<i>Excision</i> (2012).	Comedy, Drama, Horror.	1. Pauline, Troubled teen. 2. Bob, Pauline's father.
<i>Antiviral</i> (2012).	Horror, Sci-fi, Thriller.	1. Hannah Geist, Celebrity with cold sore. 2. Edward Porris, Client of the Lucas Clinic/ Obsessed fan and recipient of virus.

is characterized by a prodrome including tingling, burning, and/or pruritus at the same site of primary presentation although many cases are asymptomatic¹⁰. While the frequency and severity of HSV-1 reactivation differs between individuals, it is typically milder than primary infection, and is often contingent on emotional or physical stress stimuli such as fever, sunlight, menstruation, trauma or immunodeficiency¹¹⁻¹³. Transmission occurs via mucosal entry or direct contact with the epidermis from an infected individual shedding the virus. It is postulated that subclinical shedding represents a key factor in transmission¹⁴⁻¹⁵. Diagnosis hinges on a variety of techniques such as viral culture, serology, polymerase chain reaction, immunofluorescence, and the Tzanck smear¹⁶. There is no cure; treatment with antivirals like acyclovir and its derivatives reduce the duration of disease, frequencies of recurrence, and severity of reactivation¹⁷. Many people experience crippling feelings after diagnosis (particularly with genital herpes) such as depression, embarrassment, guilt, sexual dysfunction, fear of rejection, and fear of isolation that many physicians fail to recognize¹⁷⁻¹⁸.

The Help (2011)

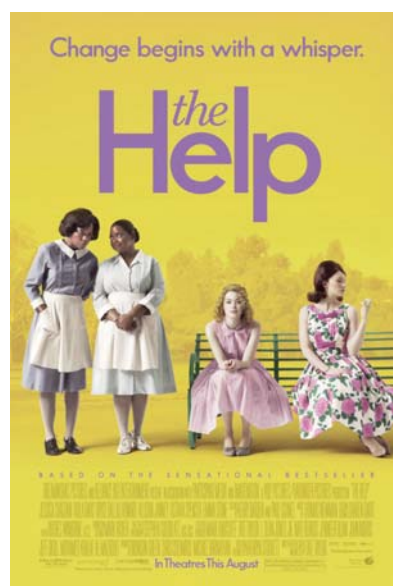The film based on Kathryn Stockett's best-selling novel was a popular and profitable feature that employed herpes to convey retribution and karma. It received four Academy Award nominations including Best Picture, and Octavia Spencer, who played the role of Minny, won in the category of Best Supporting Actress. The book and film commanded a large audience, rendering the piece an influential media source.

Set in 1960s Mississippi, the protagonist Eugenia Phelan, affectionately referred to as "Skeeter," was an aspiring writer. After graduating from college, she moved home and attempted to re-immers herself into Mississippi society. She quickly discovered all of her friends were married and had children. Though highly motivated to pursue journalism, her mother encouraged her to find a suitable man to marry in keeping with the ideals of the era. Fortunately, she acquired a writing position at the local paper and was tasked with composing the cleaning column aptly named "Homemaker Hints." Subsequently, she interviewed Aibileen Clark, the maid working at the home of Skeeter's old friend, Elizabeth. During the ensuing months, Skeeter witnessed the dynamic between her white friends and their black help, inciting deep-seated frustration. For instance, Hilly Holbrook, the queen bee of Skeeter's friends' circle was the most ungrateful. She proposed the "Home Help Sanitation Initiative" which suggested blacks are vectors for disease

and contended "separate but equal" bathrooms would protect whites from contracting these maladies.

Fueled by the desire to publish, Skeeter decided to compose an exposé of the maids' experiences. Initially, she struggled to find maids willing to participate because they feared the consequences of revealing intimate details about their employers' lives and how their contributions could negatively impact the progress of the concurrent Civil Rights Movement. Fed up with mistreatment and horrified with the direction in which the white children were heading, Aibileen agreed to tell her story to Skeeter in secret. Soon thereafter, Hilly's ex-maid, the sassy, outspoken Minny with renowned cooking skills, came forward after she was terminated for using the family's in-home bathroom during a heavy thunderstorm rather than the designated outdoor bathroom. Hilly's vindictive personality prompted her to thoroughly discourage other families from hiring Minny. To retaliate, Minny baked her famous chocolate pie and included a special ingredient, her feces, which Hilly gobbled up. This anecdote practically guaranteed Hilly would not reveal the identity of the contributors. The first draft of Skeeter's novel was well received by the editor, Elaine Stein. However, Stein requested more maids be interviewed before publication of the book. The murder of Medgar Evers, a black civil rights activist, coupled with the unfounded arrest of Minny's replacement for pawning one of Hilly's rings to send her twins to college prompted more help to come forward and contribute.

Prior to the completion of her novel, Skeeter pondered her relationship with her family maid and sec-



ond mother, Constantine. To explain Constantine's absence, Skeeter was initially told Constantine had retired to Chicago to reside with relatives. Skeptical, Skeeter uncovered the truth. Skeeter's mother, Charlotte, finally revealed that while hosting a luncheon for the Daughters of America, she fired Constantine. Constantine's slow service embarrassed Charlotte and then Constantine's daughter Rachel arrived early for a visit interrupting the gathering of eight. Charlotte requested that Rachel to go to the back door where she could wait in the kitchen, but Rachel disregarded the instructions and entered through the front door to greet her mother. Charlotte then felt pressured by the president of the organization to save face and demanded that Constantine and Rachel leave. Feeling guilty, Charlotte sent Skeeter's brother to bring Constantine home from Chicago where he discovered she had already died.

Skeeter's book was finally published and wildly successful. The maids received a portion of the royalties. Enraged, Hilly was determined to have her friend Elizabeth fire Aibileen by framing her for stealing the house silver. Aibileen responded to Hilly, "All you do is scare and lie to try to get what you want. You a godless woman. Ain't you tired, Miss Hilly? Ain't you tired?" Although Elizabeth wavered, Aibileen was fired as Elizabeth's young daughter, Mae Mobley, wept because Aibileen, her caregiver, left.

In one of the final scenes, Hilly's upper lip was plagued with a large cold sore. While drinking a beer and smoking a cigarette, she sped toward Skeeter's home to inform Charlotte of her daughter's blatant disregard of the community ideals. The lip lesion stood in stark contrast to her pale skin. She was infuriated by the success of Skeeter's novel, a work that featured her eating feces. The lesion permitted Charlotte to condemn Hilly's behavior:

Charlotte: Darlin'? Oh! No husband wants to come home and see *that*.

Hilly: Oh, I didn't have time to get it fixed up.

Charlotte: You know, Hilly? If I didn't know any better, now I'd say you'd been eatin' too much *pie*.

Hilly: Mrs. Phelan, I came here...

Charlotte: In fact, I'm *sure* of it. Now you get your raggedy ass off my porch. Go on. Get off my property! NOW! Before we all get one of those disgusting things on our lips!

Given that no identifiable source or explanation of Hilly's herpes was portrayed, a viewer may fail to discern the viral origin of the disease or its reactivation triggers. Unfortunately, some may infer the source of Hilly's cold sore was Minny's pie, implying Minny had anogenital herpes. However, no evidence was presented


to substantiate this theory. More likely, the intention of Hilly's cold sore was to convey the downfall of an ignorant and ill-intended antagonist. It was psychosocial stress that precipitated the outbreak. Hilly's affliction with an infectious disease after she championed preventative disease efforts exhibited irony. The cold sore symbolized her moral shortcomings including racism, conflict instigation, deception, and selfishness; it served as a film device for character and audience retribution.

Additional Films Using Herpes to Convey Moral Judgment

Movies have portrayed characters with orolabial herpes without mentioning the disease. For instance, *The Lord of the Rings: The Two Towers* (2002) and *The Princess Bride* (1987), both fanciful films, utilized cold sores coupled with albinism to demonize villains.

The second installment of *The Lord of the Rings* trilogy featured Middle Earth's war against two enemies, Sauron of Mordor and Saruman of Isengard. In the film, albinic Grima Wormtongue was initially aligned with Rohan, a kingdom of men, but became a puppet of Saruman. After the wizard Gandolf frees King Theoden from Saruman's control, Wormtongue was exiled. As he was banished, he sustained a lower lip laceration that evolved into a lesion suggestive of a cold sore. This coincided with his transfiguration from a faithful servant to malevolent conspirator. Further, the classic and humorous fairy tale *The Princess Bride* featured "The Albino" who sported a permanent labial cold sore along with pale skin to help define his role as a villain. He was charged with torturing prisoners of the evil Prince Humperdinck in the Pit of Despair. Both films used cold sores to disfigure sinister characters, enhancing viewer dislike and distrust.

In contrast, herpes was directly addressed in *Excision* (2012) which casted Pauline as a delusional teenager, aspiring surgeon, and social pariah who suffered from cold sores. She exhibited inordinate behavior and had recurrent psychosexual fantasies. Pauline's father, Bob, caused her infection when he resuscitated her after a drowning accident. Immediately Pauline's mother, Phyllis, condemned him for saving Pauline while he had an active lesion. Eventually, Pauline suffered virus reactivation likely from the stress inflicted by her overbearing mother. Her flawed physical appearance – her cold sores, acne, and oft-agape mouth, reflected her unacceptable thoughts and behavior. She was contrasted to her younger sister, cystic fibrosis-stricken Grace, who possessed flawless skin. The film included a scene of Pauline forcibly kissing a young man presumably to infect



him. This adeptly portrayed the undesirability of the virus and using the virus as a weapon. Pauline ultimately killed Grace and her judgmental neighbor as she attempted an allograft lung transplant in the family garage.

A Film's Unusual Exploitation of Herpes

Antiviral (2012) featured a company, The Lucas Clinic, which profited from inoculating obsessed fans with modified viruses harvested from sick celebrities in order to create an intimate bond. One of these celebrities, Hannah Geist, contracted a cold sore on her right lip. To mirror a kiss with her, character Edward Porris opted for injection of her virus into his left gingiva so the virus would reside in his left trigeminal ganglion. Protagonist Syd March was an employee of The Lucas Clinic who smuggled viruses from the clinic to sell on the black market by infecting himself. March eventually inoculated himself with a deadly virus from Geist. Facing his own mortality, he was forced to unravel the mystery behind her death. The theme centered on society's unhealthy fascination with celebrity. Uniquely, this film featured a character desiring the virus, intimating an unusual sexual fantasy.


Films Employing Herpes for Humor

Movies also use orolabial herpes for humorous purposes. *This is Spinal Tap* (1984), *Smokin' Aces* (2006), and *Pineapple Express* (2008) all adorned foolish characters with cold sores.

This is Spinal Tap, a mockumentary film, followed the world's loudest band and featured the derisive

headliners, Nigel and David. It depicted them as older, struggling rock stars with large and sporadic cold sores for comedic effect. These scenes conveyed the clichéd rock lifestyle of sex, drugs, and rock 'n' roll. Morphologically, the cold sores were exaggerated; the hyperbolic representation augmented the cold sores' comedic value.

The film *Smokin' Aces* centered on the hunt for Buddy "Aces" Israel, a Las Vegas magician, wannabe gangster, and newly turned FBI (Federal Bureau of Investigation) informant against the mob. Mob boss Primo Sparazza's million-dollar bounty on Israel and his heart fueled a race among various individuals and groups



to be the first to carry out the contract as the FBI rushed to protect him. Eventually they all collided in Lake Tahoe, Nevada at Aces' not-so-secret hideout where a lethal, bloody, and amusing battle ensued. Among these legions was a band of bounty hunters hired by Rupert "Rip" Reed to bring Aces into custody before he jumped the bail posted by Reed's law firm. Reed's character was portrayed as a disheveled, insecure and perverted alcoholic with various paraphilias. His affliction with orolabial herpes underscored him as a ludicrous, disgusting and sleazy attorney.

Finally, *Pineapple Express* revolved around a process server, Dale Denton, and his marijuana dealer, Saul, as they ran from hit men and a corrupt police officer after Dale witnessed a murder. They sought the aid of Saul's supplier, Red, who was afflicted with a distinct cold sore when they arrived. The cold sore disfigured Red for humor and reflected his morally questionable actions. Red claimed it was his first cold sore:

Dale: Hey, man, what happened to your lip?

Saul: Yeah... it looks like you've been crying or something...

Red: Um, actually, my lip, that's a cold sore. And I've never had a cold sore before, so I cried.

Saul: Dude, a cold sore? Does that mean like... herpes?

Red: Yes, that's what it means. I have herpes.

Saul: Herpes... Whoa, do you know how many, like, joints we've shared?

Red: Yes, I know, I'm a disgusting person.

Saul: Herpes is for life, bro!

Red: Yeah, well, I'm gonna try to definitely put some sort of medical ointment on it. I've been taking Vicodin; that really doesn't take down the swelling, though.

Saul: It's from that time. I told you, man! You wanted to eat that lollipop out of that stripper's snatch! You wanted to do it!

However, a more plausible explanation was virus reactivation after an earlier gunpoint interrogation by the hit men pursuing Dale coupled with his betrayal of Saul. The movie culminated in Dale and Saul's fight to preserve their lives.

Discussion

Herpes lesions are seen as disfiguring, unattractive, undesirable, shameful, and associated with sexual intimacy. Cold sores on unsavory characters help establish the contrast between the protagonists and antagonists, or good versus evil. Filmmakers harness orolabial herpes for various reasons. Fever blisters have been used to punish hypocrites (Hilly), to demonize more classic villains (Wormtongue and The Albino), to augment the complexity of characters (Pauline, Bob, and Edward Porris), and to invoke humor (David, Nigel, Rupert "Rip" Reed, and Red). Movies rely on the public misperception that moral flaws and sexual promiscuity often result in infection.

While herpes is an unwelcome infection, a significant proportion of the public suffers from the disease. Films' representation of herpes likely impacts these individuals who fear rejection and would likely prefer more positive and realistic reflections of the disease. Although the audience appreciates the punishment and demise of merciless characters as well as any source of laughter in movies, filmmakers should consider the potential negative consequences.



A child speckled with varicella or a grandparent afflicted with zoster likely evokes audience empathy whereas a cold sore tends to incite negative feelings in the viewer. This is unfortunate since these viruses are related. The key difference lies in people's understanding, or lack of understanding, about transmission. While chicken pox and shingles are infectious, they are not associated with sexual activity like cold sores. Herpetic lip lesions prompt viewers to extrapolate a character's moral failing. The audience experiences feelings of shame and fear of infection. This is a troubling miscommunication about virus transmission because orolabial herpes is usually not acquired through sexual transmission. Films' dispersion of such false health information can hamper needed discussions about disease transmission and prevention.

Suppressive treatments for herpes are currently available, and hopefully science will eventually fashion a cure and a preventative vaccine. In the meantime, filmmakers will likely continue to reinforce the public's negative impression of cold sores for characterization, ultimately perpetuating the stigma. Ideally movies could encourage the public to practice safer sex and other means to avoid contracting the virus. However, current films on this topic typically fail to address prevention and treatment. These issues are likely disregarded because the portrayal of characters with the virus serves a filmmaker's purpose. In the future, more realistic depictions of herpes in film could be used as vehicles to promote discussion of herpes with health care professionals and the general public.

References

1. Brodie M, Foehr U, Rideout V, et al. Communicating health information through the entertainment media. *Health Affairs* 2001;20(1):192-99.
2. Posner TN. The 'herpes' phenomenon: media, myths, meanings, and medicines. *Science as Culture* 2000;9(4):445-65.
3. Fleming DT, McQuillan GM, Johnson RE, et al. Herpes simplex virus type 2 in the United States, 1976 to 1994. *N Engl J Med* 1997;337(16):1105-11.
4. Lafferty WE, Downey L, Celum C, Wald A. Herpes simplex virus type 1 as a cause of genital herpes: impact on surveillance and prevention. *J Infect Dis* 2000;181(4):1454-7.
5. Smith JS, Robinson NJ. Age-specific prevalence of infection with herpes simplex virus types 2 and 1: a global review. *J Infect Dis* 2002;186(Suppl 1):S3-28.
6. Green LK, Pavan-Langston D. Herpes simplex ocular inflammatory disease. *Int Ophthalmol Clin* 2006;46(2):27-37.
7. Whitley RJ. Herpes simplex virus infections of the central nervous system. A review. *Am J Med* 1988;85(2A):61-7.
8. Anzivino E, Fioriti D, Mischitelli M, et al. Herpes simplex virus infection in pregnancy and in neonate: status of art of epidemiology, diagnosis, therapy, and prevention. *Virol J* 2009;6:40. doi: 10.1186/1743-422X-6-40.
9. Dobson CB, Itzhaki RF. Herpes simplex virus type 1 and Alzheimer's disease. *Neurobiol Aging* 1999;20(4):457-65.
10. Corey L, Adams HG, Brown ZA, Holmes KK. Genital herpes simplex virus infections: clinical manifestations, course, and complications. *Ann Intern Med* 1983;98(6):958-72.
11. Spruance SL, Overall JC, Kern ER, et al. The natural history of recurrent herpes simplex labialis: implications for antiviral therapy. *N Engl J Med* 1977;297(2):69-75.
12. Young SK, Rowe NH, Buchanan RA. A clinical study for the control of facial mucocutaneous herpes virus infections. I. Characterization of natural history in a professional school population. *Oral Surg Oral Med Oral Path* 1976;41(4):498-507.
13. Freeman ML, Sheridan BS, Bonneau RH, Hendricks RL. Psychological stress compromises CD8+ T cell control of latent herpes simplex virus type 1 infections. *J Immunol* 2007;179(1):322-8.
14. Wald A, Zeh J, Selke S, et al. Reactivation of genital herpes simplex virus type 2 infection in asymptomatic seropositive persons. *N Engl J Med* 2000;342(12):844-50.
15. Gilbert S. Oral shedding of herpes simplex virus type I in immunocompetent persons. *J Oral Pathol Med* 2006;35(9):548-53.
16. Bruce AJ, Rogers RS. Oral transmission of sexually transmitted diseases. *Clin Dermatol* 2004;22(6):520-7.
17. Kimberlin DW, Rouse DJ. Clinical practice. Genital herpes. *N Engl J Med* 2004;350(19):1970-7.
18. Vezina C, Steben M. Genital herpes: psychosexual impacts and counseling. *The Canadian Journal of CME* 2001:125-34.



Alex Christopher Holliday, MD is a 2008 magna cum laude graduate of Texas A&M University, College Station, Texas where he majored in biomedical sciences and a 2012 cum laude graduate of The University of Texas Medical Branch (UTMB), Galveston, Texas. He is currently training in Internal Medicine at UTMB as he pursues his ultimate goal of a career in dermatology.



Amanda Salih graduated from the University of Texas at San Antonio in 2008 with a degree in sociology and pre-medicine. This was followed by a Master of Public Health degree from the University of Michigan in 2010. She will graduate from The University of Texas Medical Branch in Galveston with an MD degree in 2014, and is planning on taking a residency in pediatrics.



Richard F. Wagner, Jr., MD is currently the Edgar B. Smith Professor of Dermatology at the University of Texas Medical Branch in Galveston, Texas, USA. In addition to serving as the Program Director for the Dermatology Residency Program, he also teaches several didactic courses in the medical humanities to upper level medical students. These classes focus on analysis of literary and cinematic skin disease depictions and their impact.